Case Discussion

17/7/2017

Int1.ธนาภรณ์ โชติเอี่ยม

Objectives

- Approach to Acute RLQ pain in female
- Diagnosis of Acute appendicitis
- Treatment of Acute Pelvic inflammatory disease

Patient identification

- ผู้ป่วยหญิงไทย อายุ 18 ปี G1P1 last 1 ปี, no underlying disease
- รับไว้ในโรงพยาบาลภูเขียว 21/06/2017
- CC : ปวดท้อง 2 วัน PTA
- PI : 2 วันPTA ผู้ป่วยมีไข้ ร่วมกับรู้สึกปวดท้องทั่วๆ โดยเฉพาะบริเวณกลางท้อง มีคลื่นไส้อาเจียน 1 ครั้ง ถ่ายเหลว 1 ครั้ง

  5 ชั่วโมงPTA ผู้ป่วยมีไข้สูง ปวดท้องย้ายมาปวดที่ท้องน้อยด้านขวา ปวดบีบๆเป็นพักๆ ปวดมากขึ้น pain score 10/10 คลื่นไส้อาเจียนเป็นน้ำลาย 4-5 ครั้ง ถ่ายเหลว 6-7 ครั้ง ไม่มีมูกเลือดปน อ่อนเพลีย กินอาหารไม่ค่อยได้ ปัสสาวะปกติ ไม่มีเลือดออกทางช่องคลอด ไม่มีตกขาวผิดปกติ ไม่มีไอ เจ็บคอ น้ำมูก ไม่เคยมีอาการแบบนี้มาก่อน อาการไม่ดีขึ้น จึงมารพ.ภูเขียว

Patient identification

- PH :
  - No underlying disease
  - No history of surgery
  - No current medication
  - No allergy
  - G1P1 last 1 ปี
  - LMP ปลายเดือนพ.ค.
  - ฝัง Implanon Left arm 11 เดือนที่ผ่านมา
  - มีประวัติ unsafe SI
- FH :
  - No history of cancer

Physical Examination

- **Vital signs :** BT 38.9 C, BP 100/60 mmHg, PR 158 bpm full and regular, RR 22 /min
- BW 43 kg, O2sat 100% RA
- **General appearance :** Good consciousness, looked fatigue, no pallor, no jaundice, no cyanosis
- **HEENT :** not pale conjunctivae, no icteric sclerae, pharynx not injected, tonsil not enlarged, dry lips, no sunken eyeballs
- **Respiratory system :** clear and equal breath sound

Physical Examination

- **Cardiovascular system :** tachycardia, pulse full and regular, normal S1, S2 , no murmur
- **Abdomen :** no surgical scar, normoactive bowel sound, tender at RLQ, guarding, no rebound tenderness
- **Extremities :** no edema, no rash, no wound

Physical Examination

- PV : MIUB
  - Vagina – massive purulent discharge, normal mucos
  - Cervix – marked cervical motion tenderness., massive purulent discharge per os
  - Uterus – normal size of uterus, tender
  - Adnexa – can’t be palpated abnormal mass, tender both side Rt. > Lt
  - Cul de sac – no bulging

Problem lists

- Acute fever with acute RLQ pain with GI symptoms in sexually active young women
- PV : purulent discharge per os, marked cervical motion tenderness, tender at both adnexa Rt.>Lt.

Differential Diagnosis

- GI
  - Acute appendicitis
  - Infectious gastroenteritis
  - Inflammatory bowel disease
  - Irritable bowel syndrome
  - Bowel obstruction
  - Diverticulitis
  - Mesenteric adenitis
  - Hernia
  - Tumor
- GU
  - Urinary tract infection
  - Renal/Ureteric colic
- OB-GYNE
  - Ectopic pregnancy
  - Pelvic inflammatory disease
  - Torsion ovarian cyst/tube
  - Tubo-ovarian abscess
  - Ovarian cyst ruptured

Differential Diagnosis

I. Acute appendicitis

II. Acute Pelvic inflammatory disease

III. Adnexal torsion

I. Acute Appendicitis

Table 30-2

Scoring systems

ALVARADO SCORE[37]		APPENDICITIS INFLAMMATORY RESPONSE SCORE[38,39]	
Findings	**Points**	**Findings**	**Points**
Migratory right iliac fossa pain	1	Vomiting	1
Anorexia	1	Pain in the right inferior fossa	1
Nausea or vomiting	1	Rebound tenderness or muscular defense	
Tenderness: right iliac fossa	2	Light	1
Rebound tenderness right iliac fossa	1	Medium	2
Fever ≥36.3°C	1	Strong	3
Leukocytosis ≥10 × 10^9 cells/L	2	Body temperature ≥38.5°C	1
Shift to the left of neutrophils	1	Polymorphonuclear leukocytes	
		70%–84%	1
		≥85%	2
		White blood cell count	
		10.0–14.9 × 10^9 cells/L	1
		≥15.0 × 10^9 cells/L	2
		C-reactive protein concentration	
		10–49 g/L	1
		≥50 g/L	2

= 7/10

Score: <3: Low likelihood of appendicitis
4–6: Consider further imaging
≥7: High likelihood of appendicitis

Score: 0–4: Low probability. Outpatient follow-up.
5–8: Indeterminate group. Active observation or diagnostic laparoscopy.
9–12: High probability. Surgical exploration.

Schwartz's Principles of Surgery 10th edition

II. Acute Pelvic inflammatory disease

- Symptoms
  - Purulent vaginal discharge
  - Sometimes nausea and emesis

Berek & Novak's Gynecology 15th edition

II. Acute Pelvic inflammatory disease

- Signs
  - Vital signs : elevated temperature, tachycardia
  - Abdominal examination :
    - Distention and decreased bowel sound caused by secondary ileus
    - Marked directed and rebound abdominal tenderness
  - PV :
    - Cervical motion tenderness
    - Bilateral adnexal tenderness

Berek & Novak's Gynecology 15th edition

II. Acute Pelvic inflammatory disease

- The Centers for Disease Control and Prevention guidelines for diagnosing PID state
  - High risk for STIs
  - Pelvic or lower abdominal pain
  - Uterine, cervical, or adnexal motion tenderness on exam
  - Oral temperature of 38.3 C or higher
  - Abnormal cervical or vaginal mucopurulent discharge or cervical friability
  - Presence of abundant numbers of WBCs on saline microscopy of vaginal secretions (eg. >15 to 20 WBCs per hpf or more WBCs than epithelial cells)
  - Documentation of cervical infection with N. gonorrhea or C. trachomatis

II. Acute Pelvic inflammatory disease

- The Centers for Disease Control and Prevention guidelines for diagnosing PID state
  - Elevated CRP or ESR
  - Pelvic imaging : thickened, fluid-filled tubed/oviducts with or without free pelvic fluid, or tubo-ovarian complex
  - Laparoscopic abnormalities : tubal erythema, edema, and adhesions; purulent exudate or cul-de-sac fluid; and abnormal fimbrae
  - Histological evidence of endometritis in a biopsy

II. Acute Pelvic inflammatory disease

- Indication for hospitalization
  - Pregnancy
  - Lack of response or tolerance to oral medications
  - Nonadherence to therapy
  - Inability to take oral medication due to nausea and vomiting
  - Severe clinical illness : high fever, nausea, vomiting, severe abdominal pain
  - Complicated PID with pelvic abscess (including tuboovarian abscess)
  - Possible need for surgical intervention or diagnostic exploration for alternative etiology (eg, appendicitis)

II. Acute Pelvic inflammatory disease

- **Treatment**
  - Polymicrobial infection
  - The most organisms : Chlamydia trachomatis, Neisseria gonorrhoeae
- **Inpatient therapy : first-line therapies**
  - **Cefoxitin** (2 g iv q 6 hr) or **Cefotetan** (2 g iv q 12 hr) **+ Doxycycline** (100 mg po q 12 hr)
  - **Clindamycin** (900 mg iv q 8 hr) **+ Gentamicin** loading dose (2 mg/kg of BW) followed by a maintenance dose (1.5 mg/kg) q 8 hr. single daily iv dosing of Gentamicin may be substituted for three times daily dosing

II. Acute Pelvic inflammatory disease

- **Outpatient therapy : first-line therapies –** with or without **metronidazole** (500 mg twice a day for 14 days)
  - **Ceftriaxone** (250 mg im in a single dose) **+ Doxycycline** (100 mg po twice a day for 14 days)
  - **Cefoxitin** (2 g im in a single dose) concurrently with **probenecid** (1 g po in a single dose) **+ Doxycycline** (100 mg po twice a day for 14 days)
  - Other parenteral 3rd-generation cephalosporins, such as **Cefotaxime** (1 g im in a single dose) or **ceftizoxime** (1 g im in a single dose) **+ Doxycycline** (100 mg po twice a day for 14 days)

III. Adnexal torsion

- Symptoms
  - Severe and constant pain
  - Frequently coincides with activity; lifting, exercise, intercourse
  - Autonomic reflex response; nausea, emesis, tachycardia, apprehension
- Signs
  - Mild temperature elevation, tachycardia
  - Leukocytosis
  - Abdomen : localized direct and rebound tenderness in the lower quadrant
  - PV : *a large pelvic mass on bimanual examination

Berek & Novak's Gynecology 15th edition

Provisional Diagnosis

- Acute appendicitis

Acute appendicitis

Reference : Schwartz’s Principles of Surgery 10th edition

Epidemiology

- Appendicitis in one of the most common surgical emergencies in contemporary medicine.
- The lifetime risk of developing appendicitis
  - 8.6% for males
  - 6.7% for females
- The highest incidence in the second and third decades of life.

Etiology and Pathophysiology

- The main etiologic factor
  - Obstruction of the lumen due to fecaliths or hypertrophy of lymphoid tissue
  - The frequency of obstruction rises with the severity of the inflammatory process

Etiology and Pathophysiology

- The proximal loop obstruction of the appendiceal lumen ⟶ a closed-loop obstruction ⟶ continuing normal secretion by the appendiceal mucosa ⟶ distension of the appendix ⟶
  - stimulates the nerve endings of visceral afferent stretch fibers ⟶ vague, dull, diffuse pain in the mid-abdomen or lower epigastrium
  - Increases from continued mucosal secretion and from rapid multiplication of the resident bacteria of the appendix ⟶ nausea and vomiting, and the visceral pain increase
- ↑A pressure in the organ ⟶ ↑venous pressure but arterial inflow continue ⟶engorgement and vascular congestion

Etiology and Pathophysiology

- The inflammatory process soon involves the serosa of the appendix ⟶ and in turn the parietal peritoneum ⟶ the characteristic shift in pain to the right lower quadrant
- The mucosa of the appendix is susceptible to impairment of blood supply ⟶ bacterial invasion
  - The antimesenteric border : the poorest blood supply ⟶ Ellipsoidal infarction
- Distension, bacterial invasion, compromise of the vascular supply, and infarction progress ⟶ Perforation : usually on the antimesenteric border just beyond the point of obstruction

Microbiology

- Escherichia coli
- Bacteroides : gangrene of perforated appendicitis
- Fusobacterium nucleatum/necrophorum

Clinical Presentation

Symptoms	Sensitivity %	Specificity %
1. Periumbilical pain, diffuse pain ⟶ RLQ pain	81	53
2. Nausea	58	36
3. Vomiting	51	45
4. Anorexia	68	36

- GI symptoms >> Pain : Gastroenteritis
- Diarrhea : association with perforation, especially in children

Clinical Presentation

- **Vital signs :** may be minimally altered
- **Abdomen :** peritoneal irritation
  - move slowly and prefer to lie supine
  - Tenderness with a maximum at or near McBurney's point
  - Guarding in the right iliac fossa
  - Rebound tenderness
  - *Indirect tenderness (Rovsing's sign)
  - *Indirect rebound tenderness
  - Psoas sign, Obturator sign

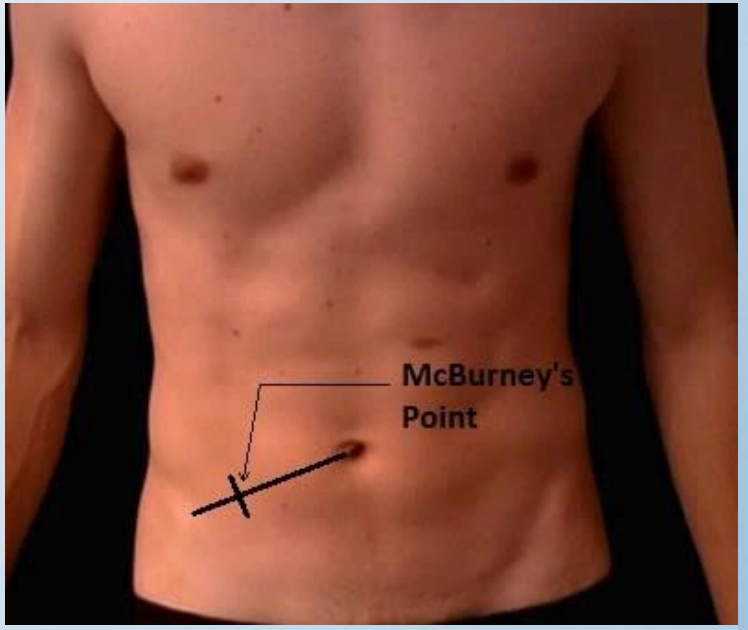

Case

- ปวดท้องบริเวณกลางท้อง แล้วย้ายมาปวดที่ท้องน้อยด้านขวา ปวดมากขึ้น pain score 10/10
- ไข้
- คลื่นไส้อาเจียนเป็นน้ำลาย 4-5 ครั้ง ถ่ายเหลว 6-7 ครั้ง
- **Vital signs :** BT 38.9 C, BP 100/60 mmHg, PR 158 bpm full and regular, RR 22 /min
- **Abdomen :** no surgical scar, normoactive bowel sound, tender at RLQ, guarding, no rebound tenderness

Investigation

Table 30-2

Scoring systems

ALVARADO SCORE[37]		APPENDICITIS INFLAMMATORY RESPONSE SCORE[38,39]	
Findings	**Points**	**Findings**	**Points**
Migratory right iliac fossa pain	1	Vomiting	1
Anorexia	1	Pain in the right inferior fossa	1
Nausea or vomiting	1	Rebound tenderness or muscular defense	
Tenderness: right iliac fossa	2	Light	1
Rebound tenderness right iliac fossa	1	Medium	2
Fever ≥36.3°C	1	Strong	3
Leukocytosis $\geq 10 \times 10^9$ cells/L	2	Body temperature ≥38.5°C	1
Shift to the left of neutrophils	1	Polymorphonuclear leukocytes	
		70%–84%	1
		≥85%	2
		White blood cell count	
		$10.0–14.9 \times 10^9$ cells/L	1
		$\geq 15.0 \times 10^9$ cells/L	2
		C-reactive protein concentration	
		10–49 g/L	1
		≥50 g/L	2
Score: <3: Low likelihood of appendicitis 4–6: Consider further imaging ≥7: High likelihood of appendicitis		Score: 0–4: Low probability. Outpatient follow-up. 5–8: Indeterminate group. Active observation or diagnostic laparoscopy. 9–12: High probability. Surgical exploration.	

Schwartz's Principles of Surgery 10th edition

Investigation (21/06/2017)

- Urine Pregnancy test : negative
- Urinalysis : Sp.gr 1.030, pH 5.0, WBC 50-100, RBC 0 , Sq.epi 1-2
- CBC :
  - Hb 14.3 g/dL, Hct 42.8 %
  - WBC 12,700 K/uL, Neutrophil 90.0 %, Lymphocyte 10.0 %
  - Platelets 197,000 K/uL
- Electrolyte
  - Na 134 mmol/L, K 3.9 mmol/L, Cl 99 mmol/L, HCO3 23 mmol/L
- BUN 17, Cr 0.75

Investigation

Table 30-2

Scoring systems

ALVARADO SCORE[37]		APPENDICITIS INFLAMMATORY RESPONSE SCORE[38,39]	
Findings	**Points**	**Findings**	**Points**
Migratory right iliac fossa pain	1	Vomiting	1
Anorexia	1	Pain in the right inferior fossa	1
Nausea or vomiting	1	Rebound tenderness or muscular defense	
Tenderness: right iliac fossa	2	Light	1
Rebound tenderness right iliac fossa	1	Medium	2
Fever ≥36.3°C	1	Strong	3
Leukocytosis $\geq 10 \times 10^9$ cells/L	2	Body temperature ≥38.5°C	1
Shift to the left of neutrophils	1	Polymorphonuclear leukocytes	
		70%–84%	1
		≥85%	2
		White blood cell count	
		$10.0–14.9 \times 10^9$ cells/L	1
		$\geq 15.0 \times 10^9$ cells/L	2
		C-reactive protein concentration	
		10–49 g/L	1
		≥50 g/L	2

= 9/10

Score: <3: Low likelihood of appendicitis
4–6: Consider further imaging
≥7: High likelihood of appendicitis

Score: 0–4: Low probability. Outpatient follow-up.
5–8: Indeterminate group. Active observation or diagnostic laparoscopy.
9–12: High probability. Surgical exploration.

Schwartz's Principles of Surgery 10th edition

Investigation

Imaging	Sensitivity %	Specificity %	Advantage	Disadvantage
1. Ultrasonography	55 – 96	85 – 98	- Inexpensive - Rapidly - No contrast - Children, pregnancy	- Operator dependent
2. CT scan	92 – 97	85 – 94	- High sensitivity, specificity, accuracy - Lowered rate of negative appendectomy	- Expensive - Expose to radiation - Limited in pregnancy - Allergy

Investigation (22/06/2017)

- CT lower abdomen with contrast :
  - Enlargement of appendix measured about 1.4 cm in diameter with adjacent free air, ruptured acute appendicitis is suggested.
  - minimal ascites in pelvic cavity.

REPORT FOR RADIOLOGY EXAMINATION
PHUKIEO HOSPITAL

[redacted] อายุ -- เพศ หญิง สิทธิ บัตรประกันสุขภาพถ้วนหน้า(ชำร
HN 0047372 แพทย์ แผนก
วันที่ แพทย์อ่านผล วันอ่านผล 22/06/2017

CT LOWER ABDOMEN WITH CONTRAST

HISTORY: Rule out appendicitis.

FINDINGS: The study reveals enlargement of appendix measured about 1.4 cm in diameter with adjacent free air, rupture acute appendicitis is suggested.
Minimal ascites in pelvic cavity is noted.
The urinary bladder, uterus, and adnexa are unremarkable.
No significant pelvic lymphadenopathy is found.
Bony structure is intact.

IMPRESSION
- Enlargement of appendix measured about 1.4 cm in diameter with adjacent free air, rupture acute appendicitis is suggested.
- Minimal ascites in pelvic cavity.

Panadda, MD
Radiologist

Differential diagnosis

- 4 major factors
  - Anatomic location of the inflamed appendix
  - Stage of the process (uncomplicated or complicated)
  - Patient's age
  - Patient's gender

Differential diagnosis

- Pediatric patient
  - Acute mesenteric adenitis
- Elderly patient
  - Diverticulitis
  - Perforating carcinoma of the cecum or of a portion of the sigmoid
- Female patient
  - Pelvic inflammatory disease
  - Ruptured Graafian follicle
  - Twisted ovarian cyst or tumor
  - Endometriosis
  - Ruptured ectopic pregnancy

Differential diagnosis

- **Pelvic inflammatory disease**
  - Usually bilateral
  - Nausea and vomiting : 50%
  - Pain and tenderness are usually lower
  - Cervical motion tenderness
  - Purulent vaginal discharge : intracellular diplococci

Management

- Uncomplicated appendicitis
- Complicated appendicitis

- Nonoperative
- Operative
  - Open Appendectomy
  - Laparoscopic Appendectomy

Management (22/6/2017, 16.00)

One day	Continue
Set OR for Appendectomy - NPO - 0.9%NaCl 1,000 ml iv rate 80 ml/hr - CXR, EKG 12 leads - Anti-HIV - G/M PRC 2 u - Cefoxitime 1 gm iv to OR	- Off Cefoxitime, Doxycyclin - Ceftriaxone 2 gm iv od - Metronidazole 500 mg iv q 8 hr

Management (22/6/2017, 18.00)

One day	Continue
Post-op order for Appendectomy with delayed primary suture - NPO - 5%DN/2 1,000 ml iv rate 60 ml/hr คู่กับ Acetar 1,000 ml iv rate 60 ml/hr x 1 ขวด - On O2 canular 2 LPM - Early ambulation - Morphine 3 mg iv prn for pain, q 4-6 hr - Record v/s q 1 hr x 2, then q 2 hr x 4 hr, then q 4 hr - Observe RR, Respiration if RR ≥ 30 pls notify - Paracetamol rectal suppo (325 mg/tab) 2 tab rectal suppo prn for fever, q 6 hr	- NPO - Record v/s Medication - Ceftriaxone 2 gm iv od - Metronidazole 500 mg iv q 8 hr

แบบ ร.ม.2 ต.05

บันทึกการผ่าตัด

Date of operation 22 มิย.60 Time 16.00 Time 16.45

Started Ended

Surgeon นพ.วรวิทย์ First assistant ศุภการิตน์

Second assistant Surgical nurse วิมลวรรณ

Clincal diagnosis Acute Appendicitis c̄ RID

Post - operative diagnosis Ruptured Appendicitis

Operation Appendectomy c̄ Drainage i' Clean

Anesthesia GA c̄ EPP Anesthesist นรา / ศุภวิทย์

DESCRIPTION OF OPERATION

Position : Supine

Procedure : - Skin was incised good 2cm

- Abdominal wall identified layer by layer

- Appendix was identified → Ruptured Appendix c̄ feculith

- Appendectomy was done c̄ double ligation

- pus suction was done, many stump

- Skin wound closed layer by layer

- Drainage i' clean

BO2 2000

Postoperative care and Complications

- Uncomplicated appendectomy
  - Diet and discharged home
  - Unnecessary post-op antibiotics
- Complicated appendectomy
  - Broad-spectrum antibiotics for 4-7 days
  - Postoperative ileus
  - Increased risk for surgical site infection

Postoperative care and Complications

- Surgical site infection
- Stump appendicitis

Hospital Course (21-27/6/2017)

Hospital Course (21/6/2017)

One day	Continue
- Admit Gyne - CBC,BUN,Cr,Electrolyte,Hemoculturex2 - UPT, UA, UC - 0.9%NaCl 1,000 ml iv rate 100 ml/hr	- Soft diet - Record vital signs Medications - Cefoxitime 2 gm iv od, stat - Doxycyclin (100) 1 tab po bid pc, stat - Paracetamol (500) 1 tab po prn for fever, q 6 hr

Investigation (21/06/2017)

- Urine Pregnancy test : negative
- Urinalysis : Sp.gr 1.030, pH 5.0, WBC 50-100, RBC 0 , Sq.epi 1-2
- CBC :
  - Hb 14.3 g/dL, Hct 42.8 %
  - WBC 12,700 K/uL, Neutrophil 90.0 %, Lymphocyte 10.0 %
  - Platelets 197,000 K/uL
- Electrolyte
  - Na 134 mmol/L, K 3.9 mmol/L, Cl 99 mmol/L, HCO3 23 mmol/L
- BUN 17, Cr 0.75

Progress note (22/6/2017)

22/6/2017	Progress note
S	ผู้ป่วยปวดท้อง PS 7/10 ถ่ายเหลว 3 ครั้ง มีไข้
O	v/s BT 37.9 C PR 108 bpm RR 22 /min BP 110/70 mmHg Lungs : clear and equal Abdomen : normoactive bowel sound, tender at RLQ, guarding, no rebound tenderness PV : purulent discharge per os
A	**Imp PID with appendicitis**
P	- NPO - CBC, CT lower abdomen with contrast - 0.9% NaCl 1000 ml iv rate 120 ml/hr

Investigation (22/06/2017)

- CBC :
  - Hb 13.1 g/dL, Hct 38.1 %
  - WBC 9,300 K/uL, Neutrophil 84.0 %, Lymphocyte 11.0 %, Monocyte 5.0%
  - Platelets 166,000 K/uL

Investigation (22/06/2017)

- CT lower abdomen with contrast :
  - Enlargement of appendix measured about 1.4 cm in diameter with adjacent free air, ruptured acute appendicitis is suggested.
  - minimal ascites in pelvic cavity.

REPORT FOR RADIOLOGY EXAMINATION
PHUKIEO HOSPITAL

[redacted] อายุ -- เพศ หญิง สิทธิ บัตรประกันสุขภาพถ้วนหน้า(ชำร
HN 0047372 แพทย์ แผนก
วันที่ แพทย์อ่านผล วันอ่านผล 22/06/2017

CT LOWER ABDOMEN WITH CONTRAST

HISTORY: Rule out appendicitis.

FINDINGS: The study reveals enlargement of appendix measured about 1.4 cm in diameter with adjacent free air, rupture acute appendicitis is suggested.
Minimal ascites in pelvic cavity is noted.
The urinary bladder, uterus, and adnexa are unremarkable.
No significant pelvic lymphadenopathy is found.
Bony structure is intact.

IMPRESSION
- Enlargement of appendix measured about 1.4 cm in diameter with adjacent free air, rupture acute appendicitis is suggested.
- Minimal ascites in pelvic cavity.

Panadda, MD
Radiologist

Management (22/6/2017, 16.00)

One day	Continue
Set OR for Appendectomy - NPO - 0.9%NaCl 1,000 ml iv rate 80 ml/hr - CXR, EKG 12 leads - Anti-HIV - G/M PRC 2 u - Cefoxitime 1 gm iv to OR	- Off Cefoxitime, Doxycyclin - Ceftriaxone 2 gm iv od - Metronidazole 500 mg iv q 8 hr

Management (22/6/2017, 18.00)

One day	Continue
Post-op order for Appendectomy with delayed primary suture - NPO - 5%DN/2 1,000 ml iv rate 60 ml/hr คู่กับ Acetar 1,000 ml iv rate 60 ml/hr x 1 ขวด - On O2 canular 2 LPM - Early ambulation - Morphine 3 mg iv prn for pain, q 4-6 hr - Record v/s q 1 hr x 2, then q 2 hr x 4 hr, then q 4 hr - Observe RR, Respiration if RR ≥ 30 pls notify - Paracetamol rectal suppo (325 mg/tab) 2 tab rectal suppo prn for fever, q 6 hr	- NPO - Record v/s Medication - Ceftriaxone 2 gm iv od - Metronidazole 500 mg iv q 8 hr

แบบ ร.ม.2 ต.05

บันทึกการผ่าตัด

Date of operation 22 มิย.60 Time 16.00 Time 16.45

Started Ended

Surgeon นพ.วรวิทย์ First assistant ศุภการิตน์

Second assistant Surgical nurse วิมลวรรณ

Clincal diagnosis Acute Appendicitis c̄ RID

Post - operative diagnosis Ruptured Appendicitis

Operation Appendectomy c̄ Drainage i' Clean

Anesthesia GA c̄ EPP Anesthesist นรา / ศุภวิทย์

DESCRIPTION OF OPERATION

Position : Supine

Procedure : - Skin was incised good 2cm

- Abdominal wall identified layer by layer

- Appendix was identified → Ruptured Appendix c̄ feculith

- Appendectomy was done c̄ double ligation

- pus suction was done, many stump

- Skin wound closed layer by layer

- Drainage i' clean

BO2 2000

ฟอร์มปรอท

แบบ ร.น.2ศ.02

Date							
Day after Admission / Operation							
Pulse							
Respirations							
B.P. Systolic / Diastolic							
Wt. and Ht.							
Diet							
Fluid Intake: Oral Fluids							
Fluid Intake: Parenteral							
Fluid Intake: Total							
Fluid Output: Urine							
Fluid Output: Emesis							
Fluid Output: Drainage							
Fluid Output: Aspiration							
Fluid Output: Total							
Stools							
Urine							
Medications							

(Indicate Pulse in Red)

ด.ญ.ชิษชคาภรณ์ สุริยันต์
HN :0047372 AN :600007546
อายุ 18 ปี 11 ด. 11วัน ศึกษาศึกษา-นร.เวช
แพทย์ : วรวิทย์ สิทธิสร,นายแพทย์

Age	Hospital Number
Ward	Attending Physician

T.P.R.

F-IPD-009 (แก้ไขครั้งที่ 00-19/04/43)

Progress note (23/6/2017)

23/6/2017	Progress note
S	ผู้ป่วยปวดท้องน้อยลง เจ็บแผล ไข้ลดลง รู้สึกเหนื่อย
O	v/s BT 37.9 C PR 108 bpm RR 24 /min BP 106/72 mmHg O2sat 100 % RA Lungs : clear and equal Abdomen : absent bowel sound, tender at RLQ, no guarding, no rebound tenderness
A	**Ruptured appendicitis post-op appendectomy day 1**
P	- NPO - Continue antibiotics - Control pain by Mo. 3 mg iv prn q 4-6 hr - 0.9% NaCl 1000 ml iv rate 120 ml/hr

Progress note (24/6/2017)

24/6/2017	Progress note
S	ผู้ป่วยเจ็บแผล ไม่มีไข้ ไม่เหนื่อย
O	v/s BT 37.6 C PR 76 bpm RR 26 /min BP 100/68 mmHg O2sat 100 % RA Lungs : clear and equal Abdomen : normoactive bowel sound, tender at RLQ, no guarding, no rebound tenderness
A	**Ruptured appendicitis post-op appendectomy day 2**
P	- จิบน้ำเช้า, liquid diet เที่ยง, Soft diet เย็น - Continue antibiotics - Control pain by Mo. 3 mg iv prn q 4-6 hr - 0.9% NaCl 1000 ml iv rate 100 ml/hr

Progress note (25/6/2017)

25/6/2017	Progress note
S	ผู้ป่วยเจ็บแผลน้อยลง ไม่มีไข้ ไม่เหนื่อย
O	v/s BT 36.6 C PR 64 bpm RR 20 /min BP 94/64 mmHg O2sat 100 % RA Lungs : clear and equal Abdomen : normoactive bowel sound, tender at RLQ, no guarding, no rebound tenderness
A	**Ruptured appendicitis post-op appendectomy day 3**
P	- Set OR for suture 26/6/2017 - NPO AMN - Continue antibiotics - Control pain by Mo. 3 mg iv prn q 4-6 hr - 0.9% DN/2 1000 ml iv rate 100 ml/hr

Progress note (26/6/2017)

26/6/2017	Progress note
S	ผู้ป่วยไม่มีไข้ ไม่เหนื่อย กินได้
O	v/s BT 37.2 C PR 84 bpm RR 22 /min BP 118/72 mmHg O2sat 100 % RA Lungs : clear and equal Abdomen : normoactive bowel sound, tender at RLQ, no guarding, no rebound tenderness
A	**Ruptured appendicitis post-op appendectomy day 4 with S/P suture**
P	- Off iv - Continue antibiotics - Plan D/C 27/6/2017

Discharge (27/6/2017)

- Clinical ดี กินได้ ไม่เหนื่อย ปวดแผลน้อยลง แผลดี ไม่ซึม ไม่มีหนอง
- Home Medication
  - Cefizime (100) 2 tabs po bid pc x 7 days
  - Metronidazole (200) 2 tabs po tid pc x 7 days
  - Paracetanol (500) 1 tab po prn for pain, fever q 6 hr
- Plan : นัด F/U 4 ก.ค. 60 OPD Sx

Take home message

- Approach to Acute RLQ pain in female
  - GI, GU, OB-GYNE
- Diagnosis of Acute appendicitis
  - Clinical Scoring Systems : The Alvarado score, The Appendicitis Inflammatory Response Score
- Treatment of Acute Pelvic inflammatory disease
  - Indication for hospitalization
  - Inpatient therapy
  - Outpatient therapy